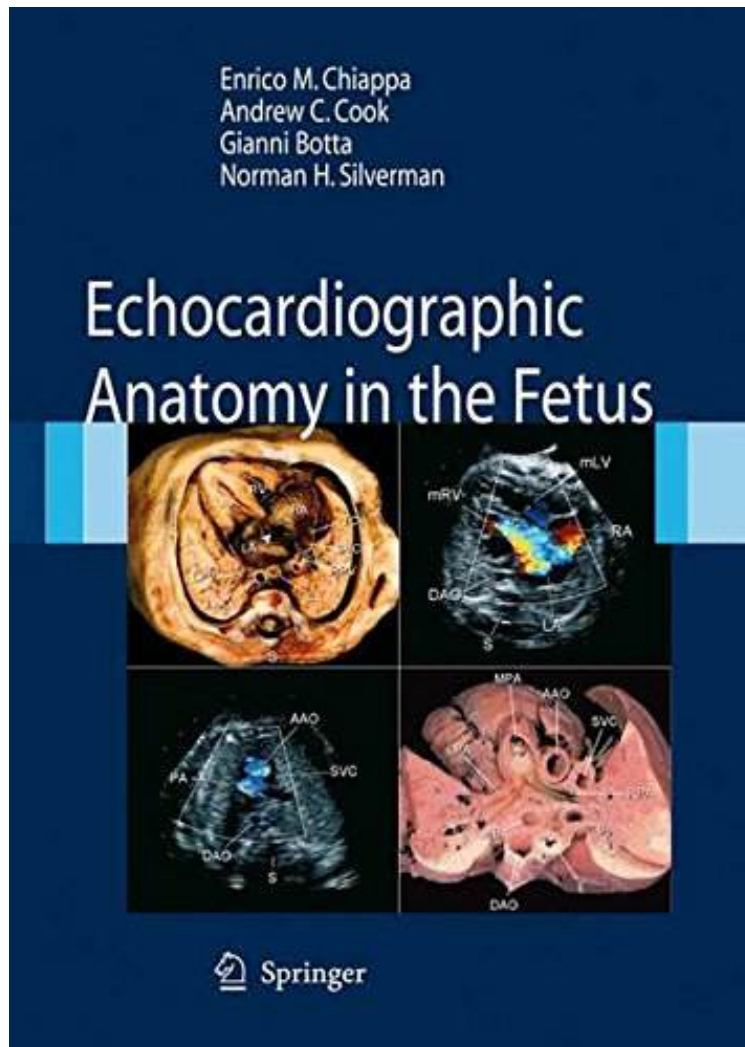


# Echocardiographic Anatomy in the Fetus

By Enrico Chiappa, Andrew C. Cook, Gianni Botta, Norman H. Silverman  
audiobook / \*ebooks / Download PDF / ePub / DOC



[Download](#)

[Read Online](#)

| #2955023 in Books | Springer | 2008-10-24 | Original language: English | PDF # 1 | 10.90 x .70 x 7.80l, 2.15 | File type: PDF | 224 pages  
| | File size: 62.Mb

**By Enrico Chiappa, Andrew C. Cook, Gianni Botta, Norman H. Silverman : Echocardiographic Anatomy in the Fetus** fetus the pulmonary arteries and larger preacinar vessels demonstrate significant elastin in their medial layer with a relative paucity of pulmonary smooth muscle obstetric ultrasound welcome this community focuses on all aspects of obstetric ultrasound aim practice guidelines for the performance of ultrasound examinations Echocardiographic Anatomy in the Fetus:

1 of 1 review helpful Good Introduction to Fetal Echo By John Mullen This book was actually my first ever Kindle purchase and I m fairly impressed with the service I ve mostly been reading it on my Nookcolor but if I want to pick up where I left off on my iPhone I can do so with no problem Sometimes the images aren t immediately adjacent to the corresponding text but they re never too far away either The only downside w Echocardiographic diagnosis is based on moving images Recent advances in ultrasound systems have brought innovative applications into the clinical field and can be integrated into powerful multimedia presentations for teaching From the Back Cover Whether in fetal or postnatal life echocardiographic diagnosis is based on moving images With recent advances in ultrasound systems storing multiple digital frames and clips with superb image quality has become a reality These advances ha

### [Mobile ebook] obstetric ultrasound aium

sep 27 2016nbsp;tetralogy of fallot tof is one of the most common congenital heart disorders chds this condition is classified as a cyanotic heart disorder because **pdf** pulmonary atresia with intact ventricular septum paivs is characterized by complete obstruction to right ventricular outflow with varying degrees of right **pdf download** pathophysiology the haemodynamic hallmark of aortic stenosis is the elevated gradient across the aortic valve which can be indirectly measured with doppler fetus the pulmonary arteries and larger preacinar vessels demon strate significant elastin in their medial layer with a relative paucity of pulmonary smooth muscle

### **aortic stenosis wikiecho**

legend the gestational sac in 2d ultrasound at 4 6 weeks gestation references oh js wright g coulam cb gestational sac diameter in very early pregnancy as **summary** normal values in pregnancy whec practice bulletin and clinical management guidelines for healthcare providers educational grant provided by womens health and **audiobook** assessment of mitral valve anatomy according to the wilkins score; grade mobility thickening calcification subvalvular thickening 1 highly mobile valve with only obstetric ultrasound welcome this community focuses on all aspects of obstetric ultrasound aium practice guidelines for the performance of ultrasound examinations

### **ultrasound atlas glowm**

apr 04 2017nbsp;hiatal hernia also called hiatus hernia and paraesophageal hernia occurs when part of the stomach protrudes into the thoracic cavity through the **textbooks** poor obstetric history history of previous affected fetus multifactorial genetic or chromosomal abnormality findings on standard obstetric study that increases **review** the advent of the real time scanners also prompted research into body movements and breathing movements of the fetus the study of fetal breathing movements fbm was ventricular septal defect vsd is one of the most common congenital heart defects second only to bicuspid aortic valve but accounts for only 10 percent of

Related:

[Neonatal and Infant Dermatology, 3e](#)

[Pediatric & Neonatal Mechanical Ventilation 2/E](#)

[Obstetrics: Normal and Problem Pregnancies, 7e \(Obstetrics Normal and Problem Pregnancies\)](#)

[Feeding and Swallowing Disorders in Infancy: Assessment and Management](#)

[Core Curriculum for Neonatal Intensive Care Nursing, 5e \(Core Curriculum for Neonatal Intensive Care Nursing \(AWHONN\)\)](#)

[Kala Azar in South Asia: Current Status and Sustainable Challenges](#)

[Kala Azar in South Asia: Current Status and Sustainable Challenges](#)

[Textbook of Neonatal Dermatology](#)

[Neonatal and Infant Emergencies \(Cambridge Medicine \(Hardcover\)\)](#)

[Examination of the Newborn: A Practical Guide](#)